

# SYNCHRONIZED RF & HIFEM: VISCERAL FAT STUDY

## VISCERAL FAT REDUCTION WITH SIMULTANEOUS APPLICATION OF HIFEM AND SYNCHRONIZED RADIOFREQUENCY ENERGIES RETROSPECTIVELY ASSESSED FROM MRI SCANS

David E. Kent MD<sup>1</sup>, Carolyn Jacob, MD<sup>2</sup>, Brian M. Kinney, MD, FACS<sup>3</sup>

1. Skin Care Physicians of Georgia, Macon, GA, USA

2. Chicago Cosmetic Surgery and Dermatology, Chicago, Illinois

3. Clinical Associate Professor of Plastic Surgery, USC Keck School of Medicine, Los Angeles, CA

Accepted at American Society for Laser Medicine and Surgery 2022, San Diego, CA

---

### HIGHLIGHTS

- 40 patients (22-62 years, BMI 21.2-34.3 kg/m<sup>2</sup>, Skin types I-VI) underwent three 30-minute treatments over the abdomen
- The MRI evaluation showed an average **reduction of -17.8%** (15.8 cm<sup>2</sup>) in visceral adipose tissue (VAT)
- The reduction in visceral fat was **homogeneous** throughout the abdomen and there were no non-responders
- The effect was maintained up to a 6-month follow-up (**-17.3%**)

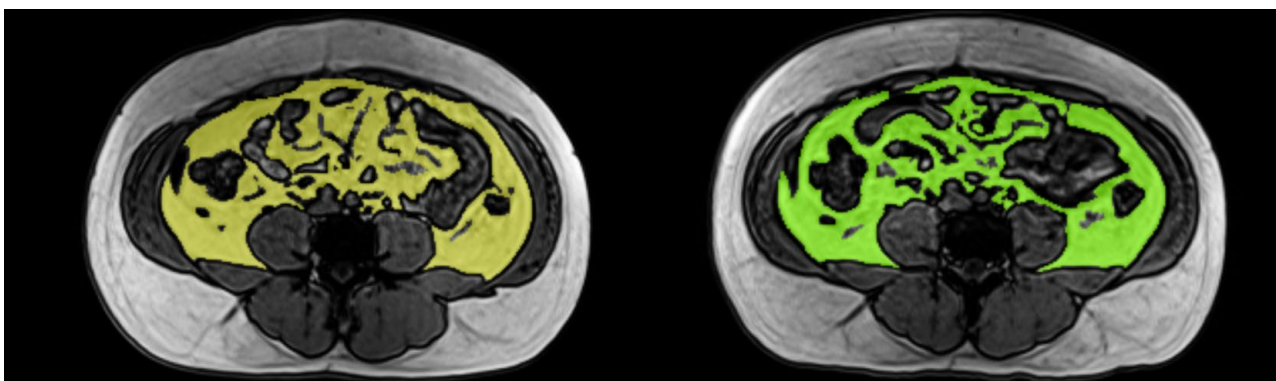


Figure 1: Visualization of visceral fat reduction, MRI image of a 34-year-old male taken at baseline (left) and at 3-month follow-up (right, a 16.4% reduction of VAT).

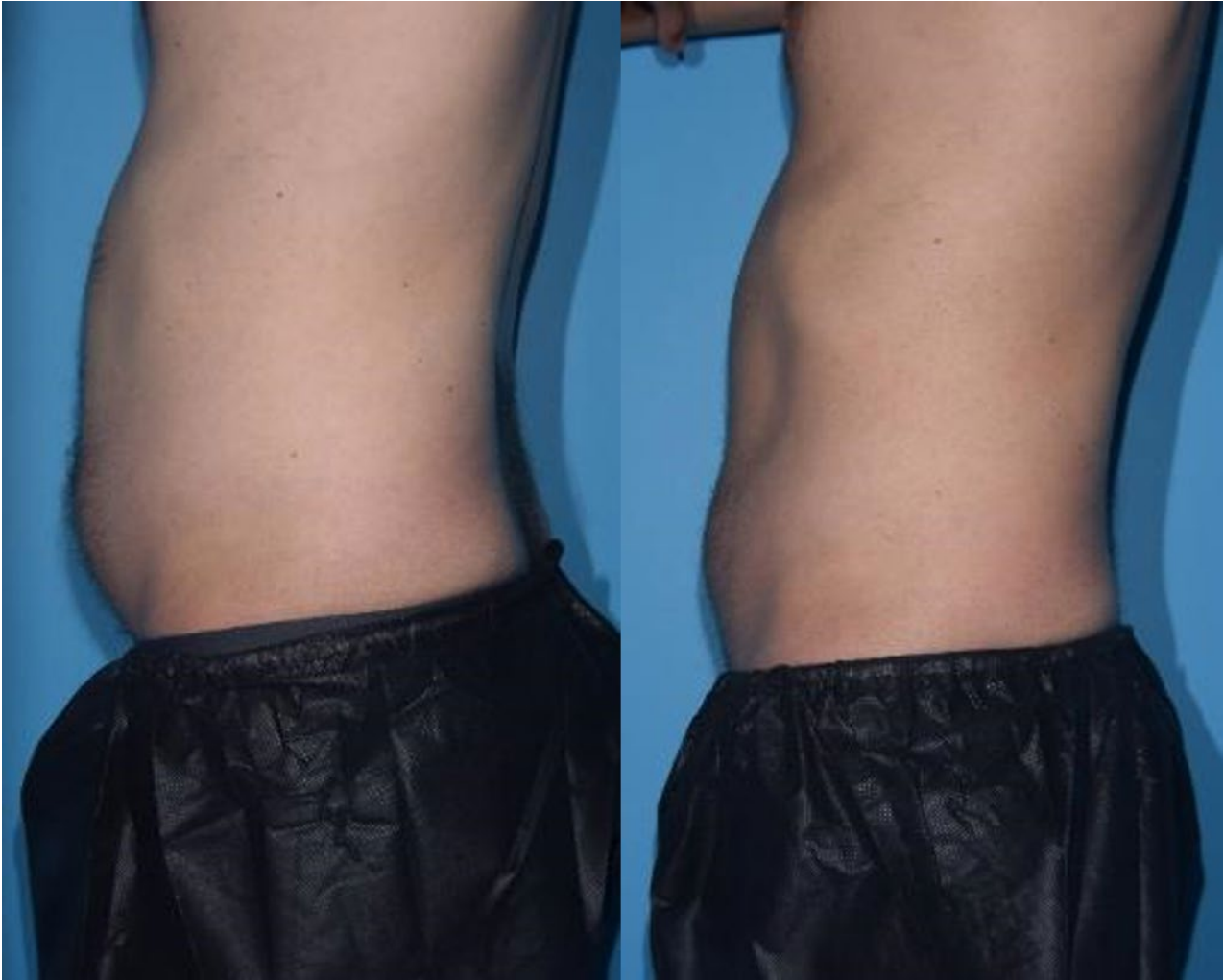

Figure 2: A digital photographs of 34-year-old male were taken at baseline (left) and 1-month follow-up (right, a 14.5% reduction of VAT).

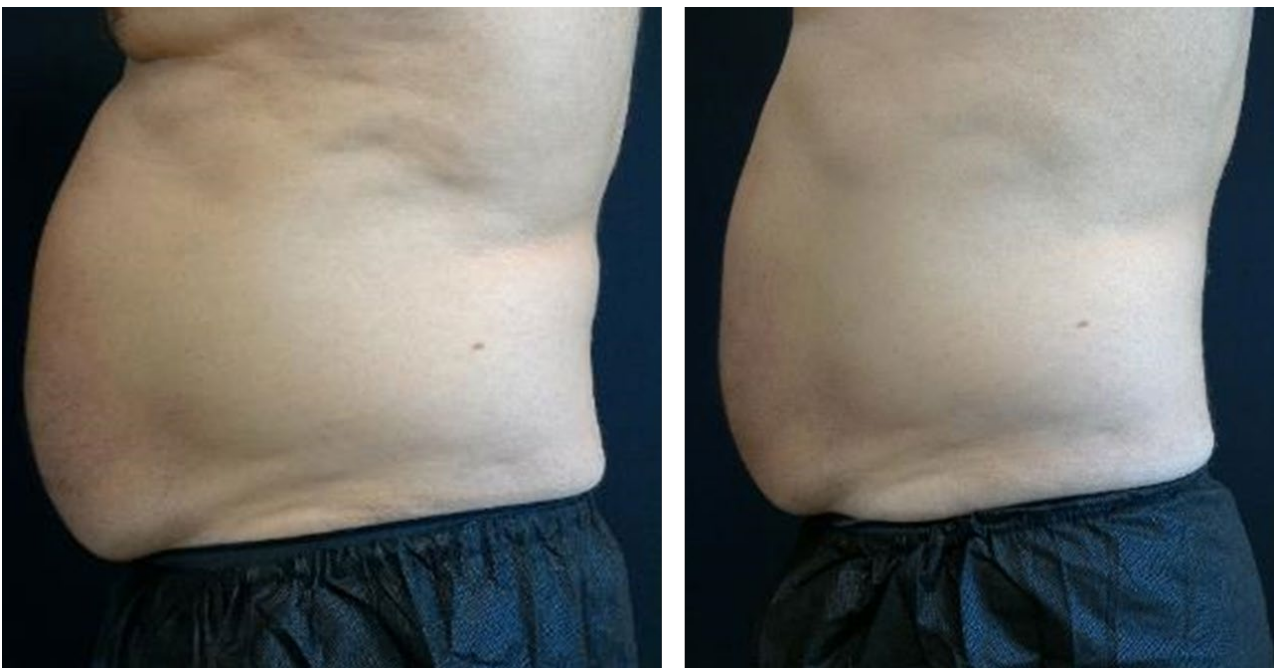

Figure 3: A digital photographs of a 57-year-old male with a BMI of 32.8kg/m<sup>2</sup> taken at baseline (left) and a 1-month follow-up visit (right, an average VAT reduction of 17.0%).